

University of Dundee

The Hall Technique

A minimal intervention, child centred approach to managing the carious primary molar



A Users Manual

Version 4

Text copyright Nicola Innes, Dafydd Evans, Matthew Stewart, Alex Keightley

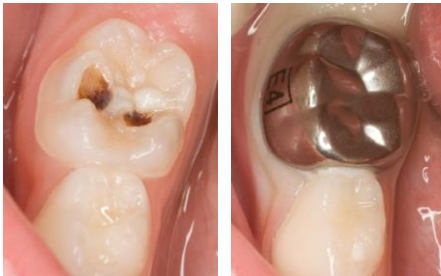Contents

Introduction	1
Background to the Hall Technique	2
Summary	7
Evidence behind the Hall Technique	9
Case selection; using the Hall Technique in clinical practice	12
Treatment planning for Hall crowns, and some important information	12
When can Hall crowns be a suitable management option for carious primary molars?	15
When is there no need to fit Hall crowns?	16
Summary	17
Fitting Hall crowns; a practical guide	18
The appointment for fitting the crown	19
Instruments to have ready	20
Step 1 of 8 Assessing the shape of the primary molar, and the occlusion	22
Step 2 of 8 Protecting the airway	26
Step 3 of 8 Sizing a crown	27
Step 4 of 8 Loading the crown with cement	27
Step 5 of 8 Fitting the crown, and first stage seating	28
Step 6 of 8 Wipe the excess cement away	30
Step 7 of 8 Check fit and second stage seating	31
Step 8 of 8 Final clearance of cement, and discharge	32
Follow Up	33
Some additional notes	36
Bibliography and further information	37
“Sealing in” caries	37
The Hall Technique	37
Final note	39

Introduction

The Hall Technique is a method for managing carious primary molars where decay is sealed under preformed metal crowns (PMCs) without local anaesthesia, tooth preparation or any caries removal.

Figure 1.
Provision of a preformed metal crown for a lower right E (85) using the Hall Technique; before, and immediately after the crown being fit



Clinical trials have shown the Hall Technique to be effective, and acceptable to the majority of children, their parents and clinicians. It is NOT, however, an easy, quick fix solution to the problem of the carious primary molar. Like all clinical interventions, for success the Hall Technique requires careful case selection, a high level of clinical skill, excellent patient management and long term monitoring. In addition, it must always be provided with a full and effective caries preventive programme (see SDCEP Guideline Prevention and Management of Dental Caries in Children <http://www.sdcep.org.uk> and SIGN Guideline 138 www.sign.ac.uk).

This manual provides information on:

- the background to the Hall Technique;
- the evidence behind the Hall Technique;
- information on case selection; and
- a “how to” guide on using the technique.

The Hall Technique will not suit every tooth, every child or every clinician. It can, however, be a useful and effective method of managing carious primary molars. This manual is intended as a guide to developing some skills in the application of the technique.

Background to the Hall Technique

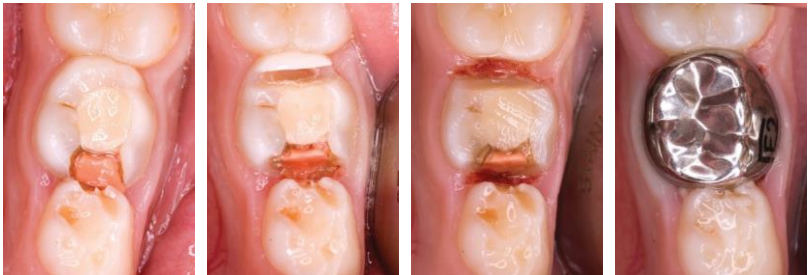How did the Hall Technique come about?

The technique is named after Dr Norna Hall, a general dental practitioner from Scotland, who developed and used the technique for over 15 years until she retired in 2006. A retrospective analysis of the outcomes for the teeth she treated in this way was published in the British Dental Journal in 2006 (Innes, 2006). This showed the technique to have outcomes comparable to conventional restorative techniques and led us to investigate it further through a randomised control trial (detailed later).

How does the Hall Technique relate to conventional crowns for primary molars?

Preformed metal crowns (PMCs), sometimes referred to as stainless steel or nickel chrome crowns, have been used for restoring primary molars since the 1950's, and have become the accepted restoration of choice for the primary molar with caries affecting more than one surface, with a proven success rate as a restoration. Although popular with specialists, many clinicians find PMCs difficult to fit using the conventional approach, which requires local anaesthetic injections and extensive tooth preparation and a high level of child co-operation (see Figure 2). There is also a high risk of damaging the adjacent first permanent molar when preparing a second primary molar for a PMC. For these, and other reasons, PMCs are not widely used in the UK, forming less than 1% of all restorations provided for children.

Figure 2.
Preparation of a mandibular second primary molar (75) for a conventional PMC.



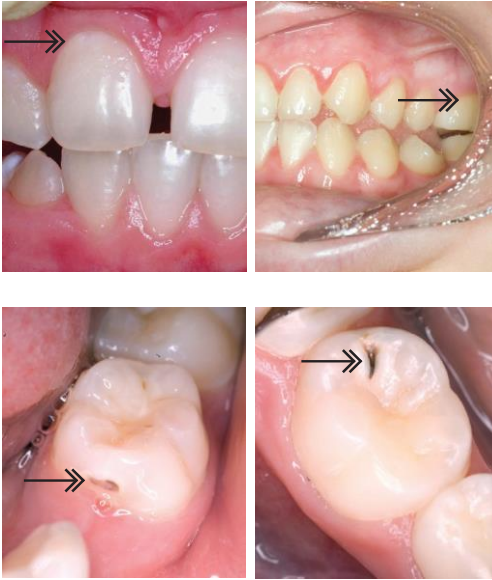
How does the Hall Technique get around some of these difficulties?

With the Hall Technique, the process of fitting the crown is quick and non-invasive. The crown is seated over the tooth with no caries removal or tooth preparation of any kind, and local anaesthesia is not required.

For decades, conventional teaching has been that all carious tooth tissue should be removed before restoring the tooth; how can leaving caries in the tooth be acceptable?

To answer this, it is worth firstly reviewing how and where caries begins. For many years it was assumed that the combination of a tooth surface, plaque and sugar would inevitably, after time, result in dental caries. However, despite the universal presence of plaque in the mouth and sugar in the diet, Clinicians will be aware that, except in extreme cases, the majority of tooth surfaces remain relatively free from caries lesions, despite many of these surfaces usually being plaque stagnation areas. Instead, 99% of caries lesions initiate on two sites which make up less than 1% of a tooth's surface; the base of pits and fissures, and just below the contact point of approximal surfaces.

Figure 3.
The varying susceptibility of tooth surfaces to dental caries, despite the almost universal presence of plaque.



Lower caries susceptibility


Higher caries susceptibility

What differs between these sites is the degree of shelter they offer to the plaque biofilm. The caries susceptible sites of fissures and the area below contact points provides plaque biofilm with sheltered micro-niches, allowing it the time and protection to mature to the level where the acidogenic bacteria (which are present in all plaque, but usually as a relatively low proportion) come to dominate the biofilm. As these acidogenic bacteria dominate the biofilm, the pH drops, eventually falling below the critical pH 5.5, at which hydroxyapatite becomes soluble, and the carious process begins. Once caries has caused cavitation of the enamel, the availability of sheltered surfaces suitable for plaque adherence, microbe colonisation and biofilm maturation dramatically increases, and so the caries lesion continues through the tooth. In summary, all plaque is potentially cariogenic, but needs a sheltered micro-niche for it to become actively cariogenic.

This points to the community of micro-organisms within plaque being extremely sensitive and responsive to changes in its environment. For cariogenic plaque, if the environment can be altered to be unfavourable for cariogenic bacteria within the community, plaque can lose its cariogenic potential.

Plaque is far from the bland, homogenous material it appears to the naked eye. Given time, and a stable environment, plaque will mature into a complex, organised structure, with channels and pores. Its bacterial population will shift and change in composition, with symbiotic relationships developing between some species, while other species will be gradually squeezed out by their neighbours. In the deeper layers, organic acids formed as a by-product of bacterial metabolism, will favour a shift in the bacterial composition from non-cariogenic species such as *Streptococcus oralis* and *Streptococcus salivarius* to more cariogenic species such as the mutans streptococci and lactobacilli. Plaque has been described by Marsh as a city of slime. This is a useful analogy because just as a city is a complex structure, whose smooth functioning can be interrupted by a change in the supply of any number of factors (food, water, oxygen, power, light), so can the cariogenic potential of plaque be altered by changing the supply of carbohydrates, oxygen, pH.

Figure 4.
The plaque biofilm as "Citadels of slime"
(after Marsh)



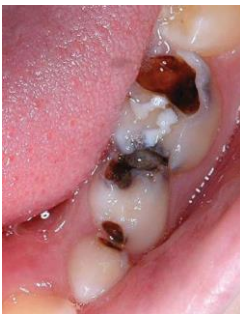DE, with apologies to "The Fantastic Voyage"

The Hall Technique manipulates the plaque's environment by sealing it into the tooth, separating it from the substrates (essentially, nutrition) it would normally receive from the oral environment. There is a possibility that the plaque may continue to receive some nutrition from perfusion through the dentinal tubules. However, there is good evidence that if caries lesions are effectively sealed from the oral environment, the bacterial profile in the cariogenic biofilm changes significantly to a less cariogenic community, and the lesion does not progress.

What about the soft dentinal lesion?

It is easy to see how an enamel lesion can be reversed but it can be difficult to imagine how we can influence a change in the soft dentinal lesion. However, most clinicians will be familiar with the clinical picture of dark, hard arrested lesions in this child's primary dentition. Perhaps because the cavity has become a cleansable shape, or the child's diet has changed, the caries lesion is no longer active and progressing; it is hard, dry and the colour has changed from pale to dark brown or black. This lesion was once wet, soft and active (evidenced by the destruction of tooth tissue), but it is now dry, hard and arrested. The evidence that caries lesions can arrest is visible to us on a daily basis, yet we continue to provide management therapies (conventional restorative treatment) based on its complete excision.

Figure 5.
Arrested caries
on primary molars
– the caries is dark
and feels hard.

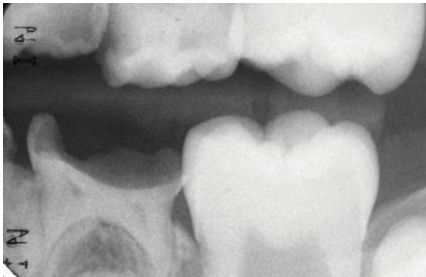

There is a Cochrane systematic review that summarises the clinical evidence around sealing caries into teeth (Ricketts et. al., 2013).

How does the pulp react to caries?

Just as it is becoming increasingly clear that dental caries is a dynamic process, it is also well established that the dentine/ pulp complex is far from passive when exposed to dental caries. Instead, these tissues mount an active defence response from the earliest stages of caries lesion formation in the enamel. Following a response from the immune system, odontoblasts are stimulated to lay down a layer of reactive dentine in an effort to distance the pulp from the approaching caries lesion, an effect readily observed, at a gross level, on radiographs.

Figure 6.
The dental pulps of primary molars responding to dental caries by the deposition of reactionary dentine



Clearly, the dental pulps of primary molars have the ability to maintain vitality and mount a defence response to dental caries, even when the dentine is involved. The reparative potential of the primary tooth dental pulp may have been underestimated.

Summary

Most plaque is not cariogenic. Plaque, which has matured in a sheltered environment to achieve cariogenic potential, can lose that potential if its environment is altered. The bacteria within the biofilm community respond to their surroundings and in an unfavourable environment, cariogenic bacteria will not continue to flourish. Effective sealing from the oral environment is one way of forcing that environmental change. This results in plaque losing its cariogenic potential for as long as the seal is maintained. The Hall Technique is one method of achieving a predictable, long term seal for primary molar teeth.



Evidence behind the Hall Technique

Is the Hall Technique effective?

To answer this question, a clinical trial set in nine general dental practices in Tayside, Scotland looked at what happened to teeth where a Hall crown was fitted, compared to teeth where a conventional restoration was placed.

The trial was a split mouth randomised control design, so teeth were matched on each side of the arch for tooth type and extent of the caries lesion. The dentists telephoned a distant site to be told which tooth to provide a Hall crown for and which tooth to manage with a standard restoration, also which to fit first (to reduce bias). 132 children were enrolled and followed up every year. The outcomes, for the children's teeth over 5 years were followed up but are summarised below. (Innes, 2007 & Innes, 2011).

Clinical outcomes

The outcomes are broken into two categories, Major Failures and Minor Failures.

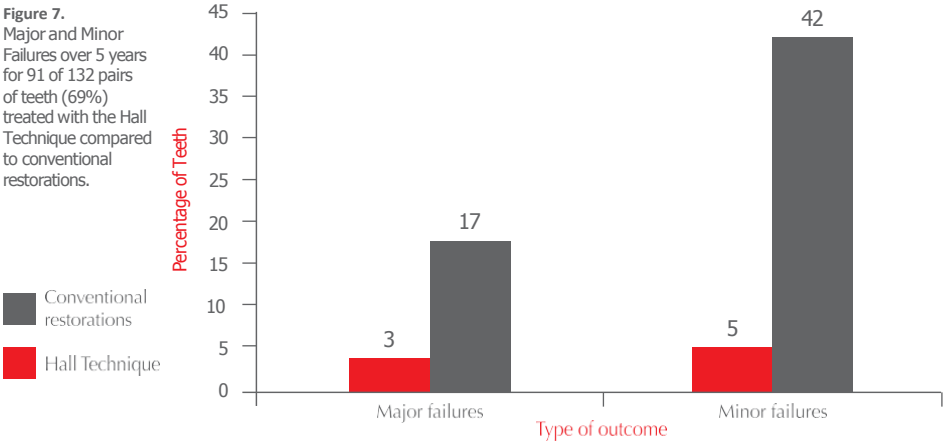
- **Major Failures**

Instances of irreversible pulpitis; where an abscess developed requiring pulpotomy or extraction; an inter-radicular radiolucency was seen on radiographs; or where the restoration was lost and tooth was now unrestorable.

- **Minor Failures**

Failures which could be resolved by replacing a failed restoration; new or secondary caries; where the filling had become worn, lost or was requiring another intervention to repair it, or where the restoration was lost but the tooth was restorable. It also included instances of reversible pulpitis that were treated simply by replacing the restoration and not requiring pulp therapy or an extraction to resolve.

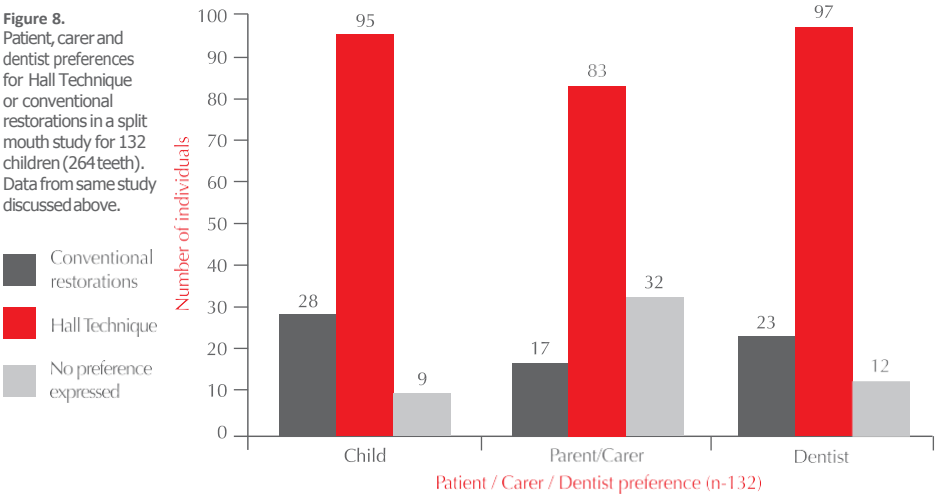
Figure 7. Major and Minor Failures over 5 years for 91 of 132 pairs of teeth (69%) treated with the Hall Technique compared to conventional restorations.



And is the Hall Technique acceptable to children, their parents and dentists?

In the same clinical trial, the children, their parents/carers and dentists stated whether they preferred the Hall or conventional restoration when both procedures were completed (see Figure 8).

Figure 8. Patient, carer and dentist preferences for Hall Technique or conventional restorations in a split mouth study for 132 children (264 teeth). Data from same study discussed above.



What about the occlusion after a Hall crown is fit

As there is no tooth reduction used to place a Hall crown, after fit a crown, the occlusion can be seen to be “propped open” on the crown (in several studies this has been noted to be an increase in OVD of around 1 – 2mm – slightly higher where crowns are placed on second primary molars than fit). The occlusion returns to balance within around 2 – 4 weeks. Recently, an observational study of 10 children who had crowns fit (So et al, 2015). Using serial study models, analysed over time using digital scanning and subtraction technology, we found that by around 4 weeks, the children’s occlusions had returned to full balance across the arches, the OVD returned to previous values (for some of the children this was sooner). It seems that the occlusion resolves mainly through intrusion of the crowned tooth and slight intrusion of the opposing teeth.

Summary

The study carried out in Tayside and a subsequent randomised trial in Germany have shown the Hall Technique to be more effective than restorations placed by the dentists, and an effective restoration in its own right. In addition, the Hall Technique was preferred to conventional restorations by the majority of the children, their parents, and dentists.

Case selection; using the Hall Technique in clinical practice

Treatment planning for Hall crowns, and some important information

Hall crowns are not a universal answer to managing all carious primary molars. They are also not a “Lazarus restoration”, used to resurrect a tooth with a poor prognosis, when all conventional techniques have failed, or are impossible to provide. Instead, with proper case selection, the Hall Technique can be an effective management option for primary molar teeth affected by dental caries. The Hall Technique will not suit every dentist, every child, or every carious primary molar in that child. Other Minimal Intervention Dentistry caries management methods are available, and should be considered, as appropriate. As with every treatment decision, clinicians should use their own clinical judgement in deciding which method is appropriate for their patient and within their own clinical capabilities to deliver, with consent being obtained from the patient, and parent, before delivering that treatment.

To begin with, exclude irreversible pulpal involvement...

A full history and clinical examination, including bitewing radiography, should be carried out. Vitality testing of primary molars with Ethyl Chloride is unreliable. Instead, dentists should use their clinical judgement in assessing the vitality, and viability, of a dental pulp, based on a thorough assessment, including:

- Clinical signs or symptoms of irreversible pulpitis, or dental abscess
- Radiographic signs or symptoms of dental abscess or pulpal involvement. When assessing a primary molar radiographically, a clear band of ‘normal’ looking dentine should be present between the carious lesion and the pulp.
- Non-physiological mobility, assessed by placing the points of a pair of tweezers in an occlusal fossa, and gently rocking the tooth bucco-lingually, and comparing with a healthy antimere
- An assessment of the extent and activity of a caries lesion, using clinical acumen to decide if there is likely to be pulpal involvement.

For example, the following are indicators of irreversible pulpal involvement, and would contra-indicate the placement of a Hall crown without pulp therapy:

Figure 9.
There is a buccal sinus associated with this maxillary first primary molar (64).

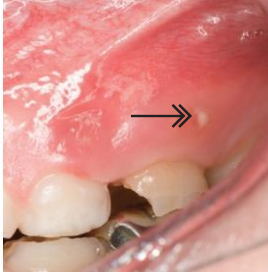

Figure 10.
This mandibular first primary molar (84) has inter-radicular pathology, indicative of a dental abscess.

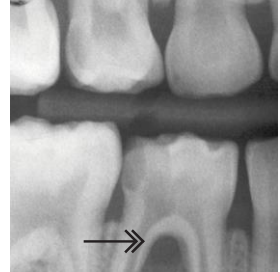


Figure 11.
This maxillary second primary molar (55) has an extensive MO cavity, and has been painful, keeping the child awake at night. This is indicative of an irreversible pulpitis, or even an abscess developing.

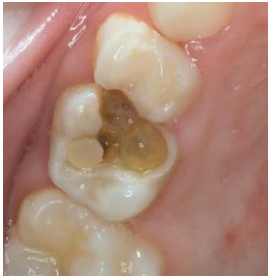

Figure 12.
Here, a mandibular first primary molar (84) which has given occasional pain, but is currently symptomless, is found to have non-physiological mobility. This, with the DO cavity and history, indicates a dental abscess.

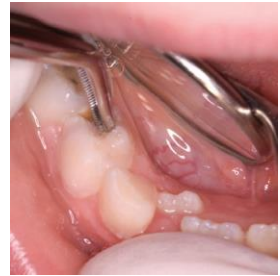

Figure 13.
This mandibular first primary molar (84) has a large distal cavity. Although symptomless, and with no inter-radicular pathology visible, there is no clear band of normal dentine between the caries and the pulp chamber. The pulp is almost certainly non-viable, and the tooth should have pulp therapy if a crown is to be placed.

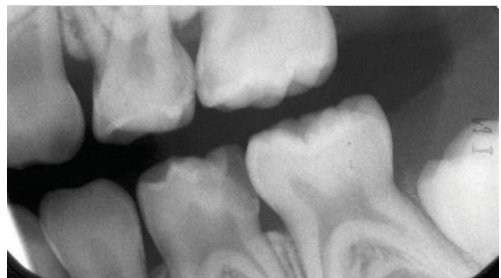
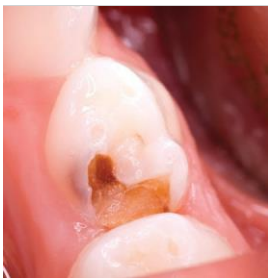
Figure 14.
This maxillary first primary molar (54) has a large distal cavity, with clinical exposure of a non-vital pulp chamber. Even in the absence of symptoms, this tooth should be extracted.

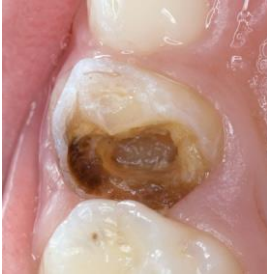

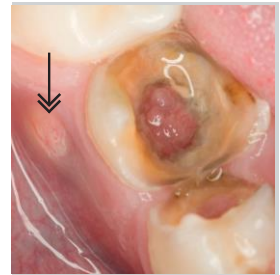
Figure 15.
This mandibular second primary molar (75) has a large occluso-lingual cavity which clearly involves the pulp chamber. Even in the absence of symptoms, the tooth should either be managed with pulp therapy or extraction.

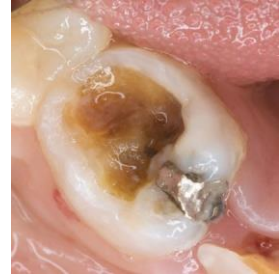

Figure 16.
This maxillary first primary molar (64) has a pulp polyp. The pulp, although exposed, is vital. In the absence of symptoms, and clinical and radiographic signs, of sepsis, it would not be unreasonable to simply monitor the tooth.

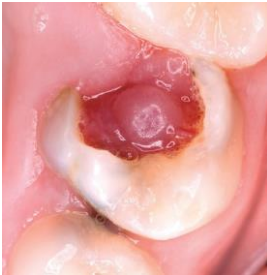

Figure 17.
However, although this mandibular second primary molar (75) has a similar pulp polyp associated with the mesial root, there is clearly a sinus associated with a non-vital distal root, and the tooth should be managed by extraction.



Clinicians should continue to monitor all primary molars managed with Hall crowns for signs or symptoms of pulpal disease at every recall visit, just as they should for all carious primary teeth managed with conventional restorations.

So, contra-indications for fitting Hall crowns include:

- Irreversible pulpal involvement (discussed above)
- Insufficient sound tissue left to retain the crown
- Patient co-operation where the clinician cannot be confident that the crown can be fitted without endangering the patient's airway
- A patient at risk from bacterial endocarditis. In such situations, the tooth should be managed with a conventional restoration which would include complete caries removal
- Parent or child unhappy with aesthetics. This should become apparent though at the treatment planning stage when treatment options are being discussed and agreed with the parent and child.

When can Hall crowns be a suitable management option for carious primary molars?

Hall crowns are a management option for active, early to moderate proximal lesions involving the dentine in primary molars with no signs or symptoms of pulpal involvement. A visible band of 'normal' appearing of dentine, between the carious lesion and the dental pulp on a bitewing radiograph is the key radiographic sign used to indicate that there is no irreversible damage to the dental pulp. The presence of this band of dentine has been shown to be a good predictor of success when a Hall crown is placed (see reference 17).

The disadvantages of the aesthetics and the bite propping will generally be counter balanced by the effectiveness of the restoration, for which there is a good evidence base.

This mandibular first primary molar (74) is appropriate for a Hall crown. The moderate distal lesion has been diagnosed reasonably early, by appropriate use of radiographs. The radiograph shows a band of sound dentine between the lesion and pulp, and no intra-radicular pathology.

Figure 18. Mandibular first primary molar, with early to moderate active caries on distal proximal surface; asymptomatic, and with a clear band of dentine between the caries lesion and the pulp, also no signs of pulpal pathology

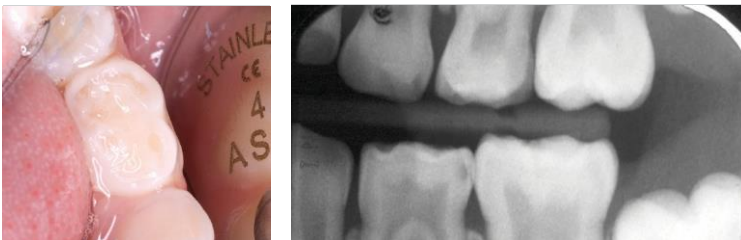
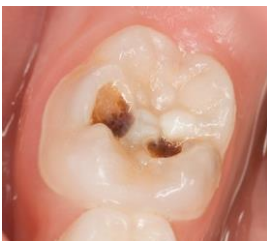

Figure 19. Moderately advanced occlusal lesions on a mandibular second primary molar (85), where due to the extent of the cavities, obtaining a good coronal seal with a partial caries removal technique might be problematic.



Hall crowns can also be suitable for the moderately advanced occlusal lesion where the extent of the cavity would make it difficult to obtain a good seal with an adhesive restorative material, following partial caries removal or where the child's behaviour precludes a successfully adhesive restoration.

When is there no need to fit Hall crowns?

Figure 20. Both maxillary and mandibular first primary molars (54 & 84) although cavitated, are clearly going to be shed soon, so are unlikely to cause pain or sepsis before exfoliation.

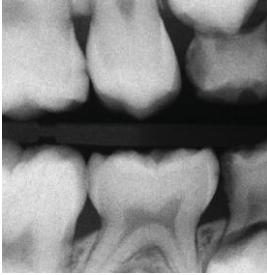

Figure 21. The mesial cavity on this mandibular second primary molar (75) is accessible, and can be managed with partial caries removal, then sealing the cavity with an adhesive restorative material, avoiding both the aesthetics and bite propping of a Hall crown.

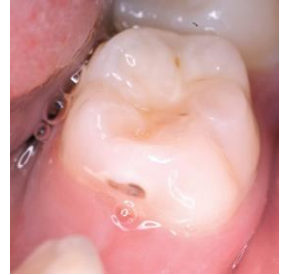

Figure 22. The cavitated occlusal lesion on this mandibular second primary molar (85) could be managed with partial caries removal, and sealing with an adhesive restorative material.

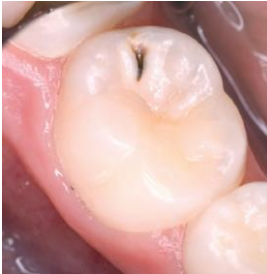

Figure 23. This mandibular second primary molar (75) has non-cavitated occlusal lesions which could be managed with a good quality, well maintained fluoride sealant.

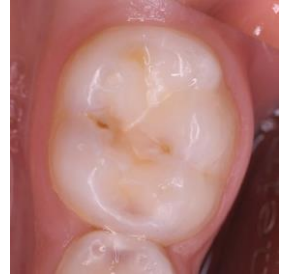

Figure 24. This mesial lesion on an upper D (tooth 64) is arrested. As the lesion is cleansable, there is no need for any management option other than prevention. However, this does depend on the carers/child continuing thorough cleaning and the tooth and the lesion must be monitored for signs of the lesion progressing.

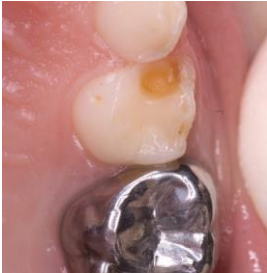
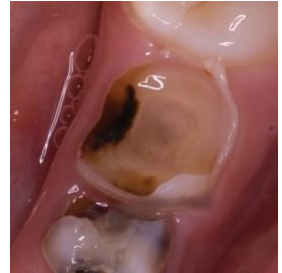
Figure 25. There is insufficient tooth tissue on this lower E (tooth 75) to allow placement of any restoration. However, the caries is arrested, the pulp is shining pink through the floor of the cavity, and in the absence of symptoms, this could be managed with prevention, and monitoring but depends on co-operation from the carers to carry out thorough cleaning.



Summary

Indications and contra-indications for using the Hall Technique for managing primary molars with caries lesions assessed as at risk of causing pain/ sepsis before exfoliation

Indications *include teeth with:*

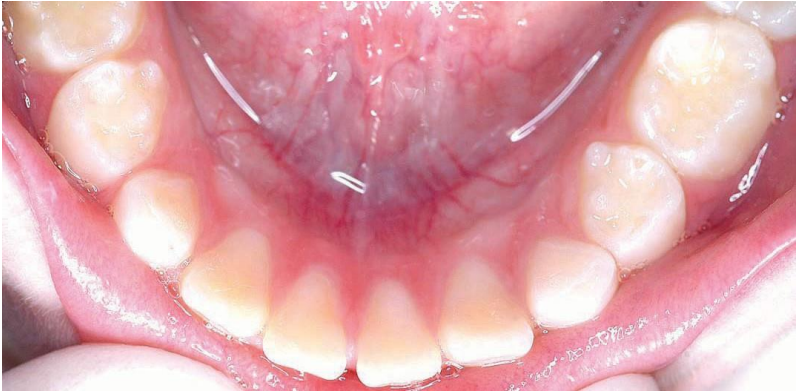- Occlusal lesions, non-cavitated
 - If patient unable to accept fissure sealant, or conventional restoration
- Occlusal lesions, cavitated
 - If patient unable to accept partial caries removal technique, or conventional restoration
- Proximal lesions, cavitated or non-cavitated

Contra-indications *include teeth with:*

- Signs or symptoms of irreversible pulpitis, or dental sepsis
- Clinical or radiographic signs of pulpal exposure, or periradicular pathology
- Crowns so broken down that they would normally be considered as unrestorable with conventional techniques

Fitting Hall crowns; a practical guide

Although apparently very simple, the Hall Technique requires a confident, skilled approach from the operator if the crown is to be successfully fitted. In addition, there are some primary molars where, for a combination of reasons, even clinicians very familiar with the Hall Technique would have difficulty successfully fit a crown.




For example, should these lower first primary molar become carious, their unusual morphology would complicate fitting a PMC of standard shape.

Again, common to all clinical procedures, it is important that the clinician has a clear understanding of how retrieve a situation which is not proceeding as planned, for example when a Hall crown is not seating properly onto a tooth or appears to be the wrong size or shape and will not fit correctly over the crown of the tooth. These issues are dealt with at the end of this section.

The appointment for fitting the crown

Preparation is everything! The child and parent should be briefed on the procedure. Children should be shown a crown, and allowed to handle a spare one if felt beneficial. Young children sometimes respond to the idea of the crown being “a shiny helmet”, or “just like soldiers wear to protect their heads”, or “a precious, shiny, princess crown” or it being a “twinkle tooth”.



It is important that the child knows that:

- a) they will have to help, by biting the crown into place when asked to do so
- b) the cement will not taste nice and can be a bit like Salt & Vinegar crisps

Instruments to have ready

Essential:

- Mirror
- Perio probe, or small spoon excavator
 - *to remove separators, if used*
- Excavator
 - *to remove crown if necessary, and*
 - *useful for cement removal*
- Flat plastic
 - *to load crown with cement*
- Cotton wool rolls
 - *for child to bite down on and push crown over tooth, and*
 - *to wipe away cement*

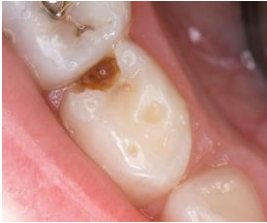Useful:

- Band forming pliers
 - *can be useful for adjusting crowns, particularly where the primary molar has lost length mesio-distally due to caries*
 - Gauze to protect the airway and wipe off excess cement
- or
- Elastoplast to secure the crown for airway protection

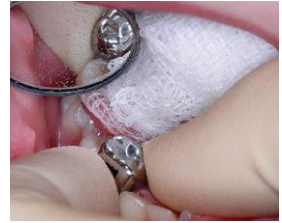Fitting a Hall crown

The practical aspects of fitting a Hall crown can be broken down into the following stages:

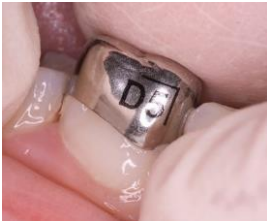Step 1.
Assessing the shape of the primary molar, and the occlusion



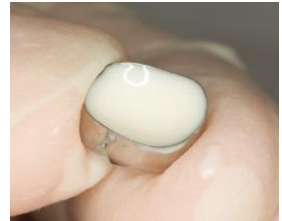Step 2.
Protecting the airway



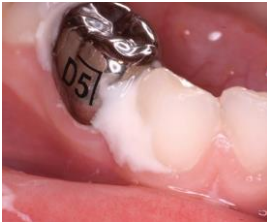Step 3.
Sizing a crown



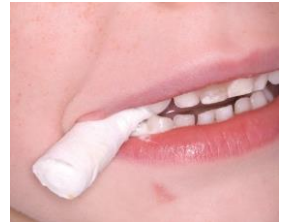Step 4.
Loading the crown with cement



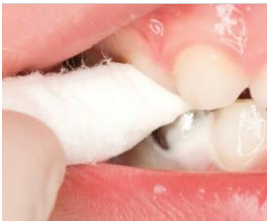Step 5.
Fitting the crown, and first stage seating



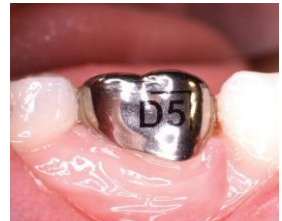Step 6.
Wipe the excess cement away



Step 7.
Check fit, and second stage seating



Step 8.
Final clearance of cement, and discharge

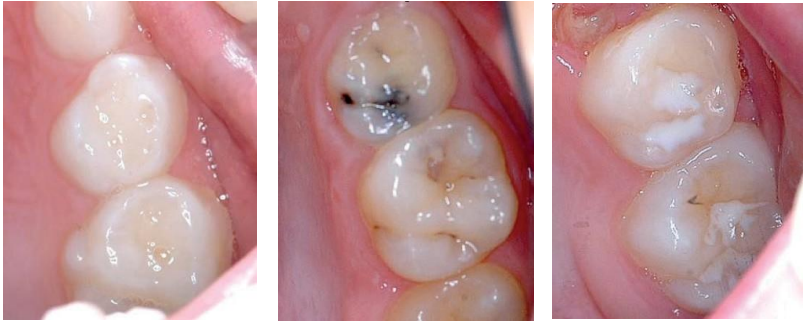

Step 1 of 8

Assessing the shape of the primary molar, and the occlusion

- a) **Tight contact points, and their management with separators**
If the contact points are broad and tight (examples of this are shown below),

Figure 26.
Tight and broad
contacts between
primary molars

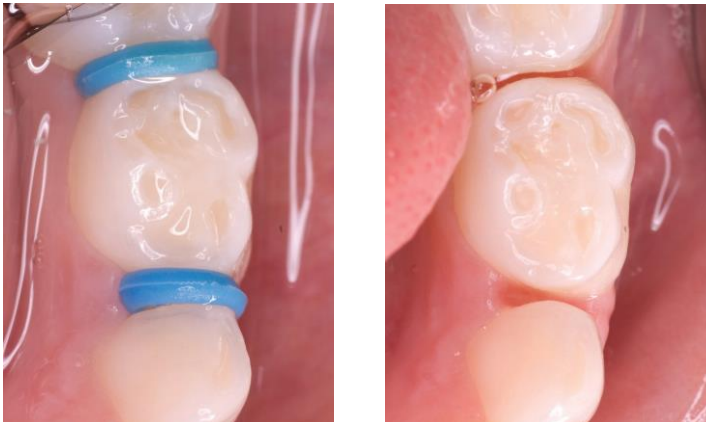

or there has been loss of mesio-distal width of a tooth due to marginal ridge fracture, placing orthodontic separators through the mesial and distal contacts can be useful when fitting crowns with the Hall Technique, although it does mean the patient will have to make a second visit. Two lengths of dental floss should be threaded through the separator. The separator should then be stretched taut, and “flossed” through the contact point briskly and firmly until the leading edge only is felt “popping through” the contact point.

Figure 27.
The use of orthodontic separators to create space for fitting a Hall crown




Figure 28.
Separators in place and space created following their removal



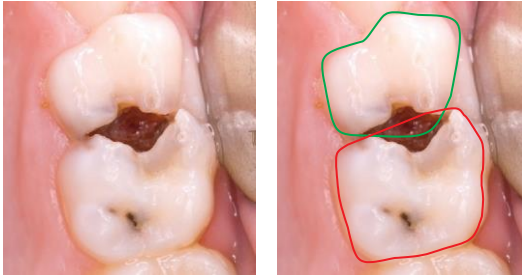
The floss should then be removed, and the patient seen 3 to 5 days later for removal of the separator.

If the separator appears to have fallen out, the inter-proximal area of the gingiva should be inspected to check that the separator hasn't worked its way below the contact point. Separators are usually brightly coloured to make them easy to see.

b) Marginal ridge breakdown

Often where there is marginal ridge breakdown in one molar, there can be migration of the adjacent molar into the cavitated area. The picture below shows an example of this. If the missing tooth walls are imagined, they will be seen to overlap. This can make placing a Hall crown difficult without making some adjustments to the tooth itself or the crown.

Figure 29. Maxillary first and second primary molars (64 & 65) with significant loss of mesio-distal dimension (in view of the extent of the dental caries, both of these teeth would require pulp therapy before fitting a PMC).

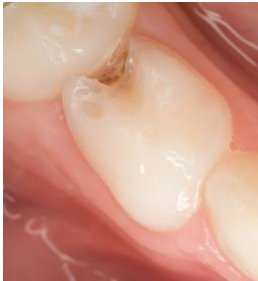

There are several ways of managing this problem if a crown cannot be fitted in the usual way:

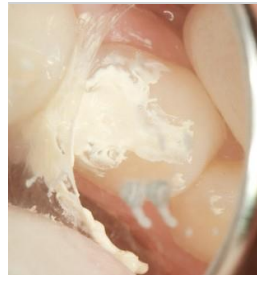- I. place a temporary restoration to rebuild the marginal ridge and allow a separator to be placed to make space for the crown to be fitted (see below);
- II. adjust of the skirt of the crown to make it fit the shape of the tooth;
- III. try a different crown; or, as a last resort,
- IV. adjust the shape of the tooth using an high speed air rotor.

i. Placing a temporary filling to allow placement of a separator

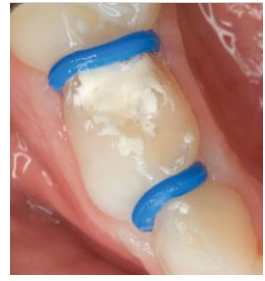Figure 30. Gentle excavation of a distal cavity on a mandibular first primary molar (74) is followed by placement of a celluloid matrix strip and a temporary dressing, allowing separator to be placed 10 minutes later



Here, a mesial cavity on an upper E is gently excavated



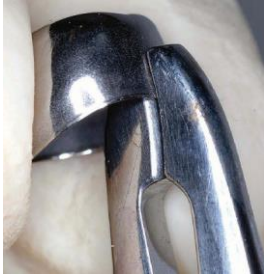Following insertion of a celluloid matrix strip, a Zinc Polycarboxylate dressing is placed



10 minutes later, when the cement is fully set, a separator is placed

ii. Adjusting the crown with band forming pliers

Figure 31. Band Forming pliers (a) being used to adjust the crown margins (b), and the effect of rotating them 180 degrees to "pinch in" a concavity to accommodate the intruding marginal ridge of an adjacent tooth (c).

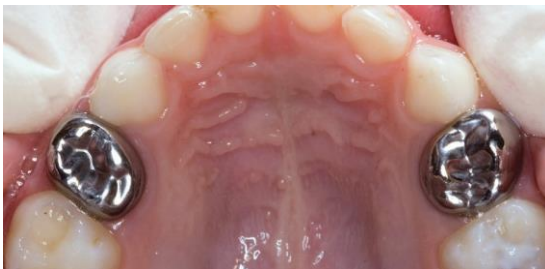

Using orthodontic band forming pliers, which have a curved surface, the margins of the crown may be adjusted. Adams pliers can also be used to adjust the crown but do not have the same curve.



Gently pinching the proximal margin of the crown with the pliers the "wrong way round" can give a concavity which may accommodate the intruding margin of the adjacent tooth.

iii. Trying a different crown



A small lower second primary molar crown may fit an upper first primary molar where there has been significant tooth loss.

c) Assessing the occlusion

Before fitting a Hall crown, check the following two points regarding the occlusion;

1. measure the anterior overbite (in order to assess the degree of propping of the bite following fitting of the crown) by checking at the canines.
2. check the buccal relationship of the tooth to be crowned with its opposing number

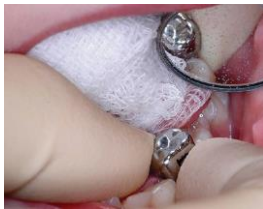Step 2 of 8 Protecting the airway

Before fitting a crown, ensure there will be no danger of the child inhaling or swallowing a loose crown (the same precautions as should be taken when fitting a conventional crown). This is most easily done by sitting the child upright. However, for upper teeth, working with the child seated upright means that the optimum operator working position has to be compromised. For lower teeth, the operator can simply move to the front or side of the child.

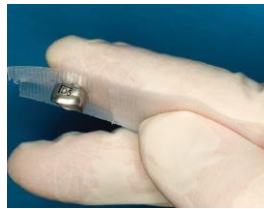
There are additional ways of protecting the airway. A gauze swab square can be placed between the tongue and the tooth where the crown is to be fitted. It should extend to the palate and round the back of the mouth in front of the fauces. Alternatively, a clean piece of Elastoplast tape can be secured to the crown (see below).

Airway protection using

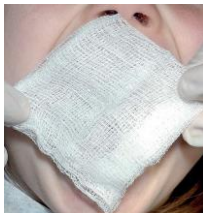Figure 33.
Protecting the
airway



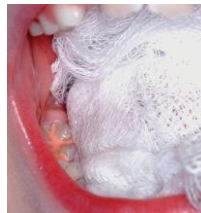a) a gauze square



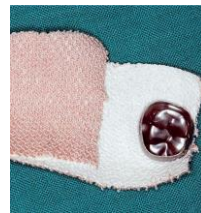b) Elastoplast



Orientation of gauze
crown



Positioned in mouth



Elastoplast tape
securing

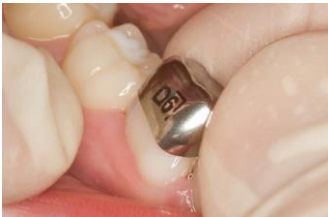If you are not confident about being able to control the crown at all stages until it is cemented, then do not use the technique.

Step 3 of 8

Sizing a crown

- Select different sizes of crowns until you find one which covers all the cusps, and approaches the contact points, with a slight feeling of "spring back".
- You should aim to fit the smallest size of crown which will seat.
- Be particularly careful not to fit an oversize crown to a second primary molar where the first permanent molar has still to erupt; this could increase the risk of first molar impaction later.
- Do not be tempted to fully seat the crown through the contact points before cementation; they can be very difficult to remove!

Figure 34.
Selecting the correct
crown size

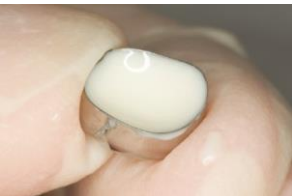

Step 4 of 8

Loading the crown with cement

- Following try in, dry the inside of the crown, using the end of a cotton wool roll.
- Load the crown generously (it should be at least two thirds) with a glass ionomer luting cement. Take care to fill the crown from the base upwards and ensure that there is cement around all the walls. Be careful to avoid air blows and voids.

Figure 35.
Loading the crown
with cement



Step 5 of 8

Fitting the crown, and first stage seating

Place the crown over the tooth. Fully seating the crown is a key stage! It is not always easy, and requires a committed, positive approach from the clinician. The child needs to have complete confidence that you know exactly what you are doing; that what you are asking them to do is perfectly reasonable, and that it will not be uncomfortable. Remember that our research and another study in Germany found that, surprisingly, most children do not find the procedure painful, and prefer it to conventional fillings. There are two main methods of seating the crowns:

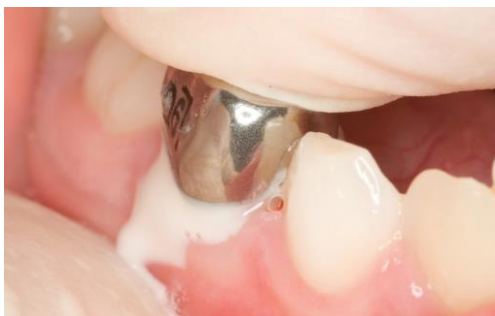- a) the clinician seats the crown by finger pressure
- b) the child seats the crown by biting on it

A combination of these two methods may be necessary or preferred.

- Some clinicians will seat the crown with firm finger pressure alone. For mandibular teeth, a useful method is to place your thumb on the occlusal surface of the crown, with the four fingers of your hand placed under the border of the mandible to spread the force as you apply firm pressure with your thumb. For maxillary teeth, the child's head may be supported by the back of the dental chair, or sometimes by placing your other forearm gently on the top of their head to balance the force applied when fitting the crown.
- Partially seat the crown until it engages with the contact points, allowing your finger to be removed without risk of the crown falling off, and the child then being encouraged to bite the crown into place. It must be remembered that your working time with glass ionomer cements is limited, and whatever method is used, you must work smoothly and efficiently. Crowns cannot be seated, no matter how hard either you or the child tries, if the cement has started to thicken.

- Often, the child will seat the crown themselves by biting it into place. It can be useful to verbally encourage the child to apply the necessary pressure ("Bite hard, like a Tiger! Grrrr...!"), and to rehearse this before fitting the crown. If using this method, be aware that some children's resolve might falter a little, leaving the crown not fully seated. Here, a timely "That was great! Now let me just check it for you! Ooh, well done, and I'll just give it a little squeeze..., Excellent!" can help.
- It is crucial that the orientation of the crown relative to the tooth is checked both during, and immediately after, seating the crown. If it does not appear to be going on straight, then you must give the crown some physical encouragement to go in the correct direction. If it is not possible to seat it then it should be removed quickly before the cement sets.
- If it is obvious that the crown has not seated, and finger pressure fails to seat it, then it should be removed immediately using the large excavator which you should have placed within easy reach. If you do not work swiftly, you may have to section the crown to remove it (see later).

Figure 36.
Fitting the crown,
and fi stage
seating



Step 6 of 8

Wipe the excess cement away

As soon as the crown is fitted, the child should be asked to open to allow the crown position to be checked again and excess glass ionomer can be wiped away.

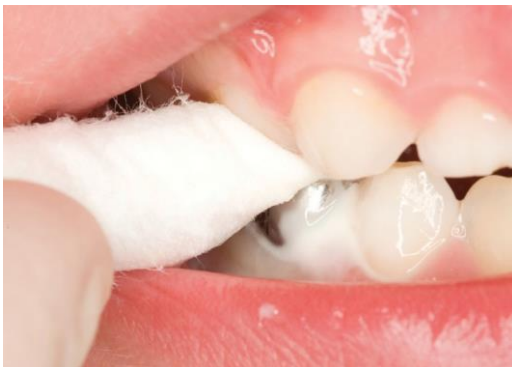- With either technique, excess cement will be extruded from the crown margins, and the taste of this can upset children. In anticipation of this, as soon as the crown is seated, the child should be asked to open their mouth, and the cement wiped off with a cotton wool roll held ready for this purpose. If a gauze swab has been used to protect the airway, this can be used to wipe away excess cement from the lingual/palatal side of the tooth as it is being removed from the mouth.

Step 7 of 8

Check fit, and second stage seating

- Once excess cement has been removed, you must make a quick visual assessment as to whether the crown is seating satisfactorily. If not, you must decide whether to try rectifying the problem (perhaps by the application of firm digital pressure), or alternatively, removing the crown before the cement sets, using the large spoon excavator you have ready for this purpose.
- If the crown is fitting satisfactorily, the child should be asked to bite firmly on the crown for 2 – 3 minutes, or the crown should be held down with firm finger pressure as an alternative. Often the crown will seat a little further, expressing more cement. This is possibly due to accommodation to the displacing pressure by the adjacent teeth.
- It is important to maintain firm pressure on the crown until the cement sets, as the crowns can spring back a short way, sucking back the cement from the margins and potentially causing breaches in the seal.

Figure 37.
Second stage
seating

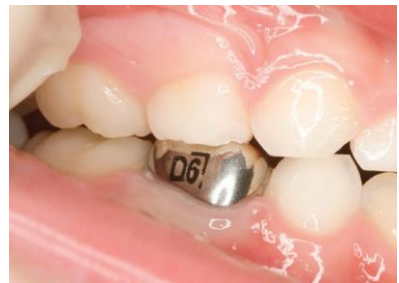
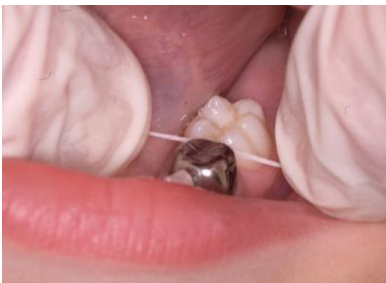
Step 8 of 8

Final clearance of cement, and discharge

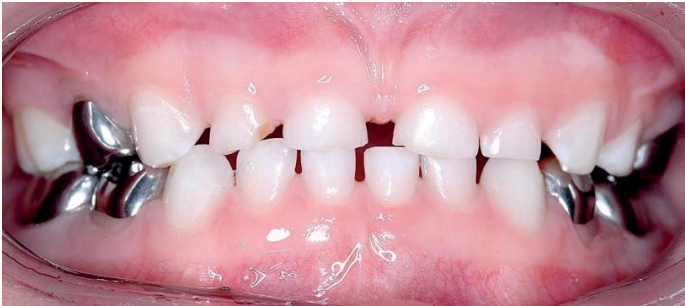- Remove excess cement, flossing between the contacts
- Blanching usually disappears within minutes. The occlusal discrepancy (here it is minimal) should resolve in a few weeks.
- Measure the degree of bite opening. If excessive, then consider either removing the occlusal part of the crown with a high speed handpiece, so that it becomes similar to an orthodontic band, or removing the entire crown.
- Check the buccal relationship of the crowned tooth with its opposing number. If there is a displacing contact, resulting in a cross bite, then manage as for excessive bite propping
- Advise the parent and child that the child will probably notice the crown as being high in the bite, but that this will no longer bother them by the following day. If there are any problems, then the child should be brought back to the surgery.
- Give the child a sticker.

Figure 38.
Final clearance
of cement, check
occlusion and
discharge



Remove any separators that have been placed.

A satisfied customer, with a restored occlusion!

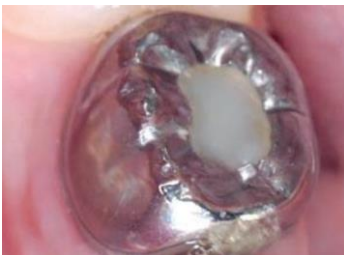

Follow Up

If the treatment planning guide has been followed for case selection, failure of Hall crowns are a rare occurrence, though like any restoration, they should be followed up both clinically and radiographically. Below, some potential complications that can occur when Hall crowns are placed are discussed, and advice given on how to manage these.

Sepsis

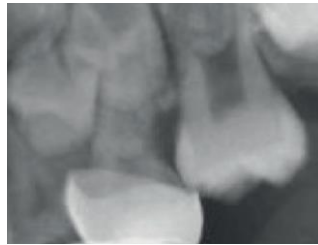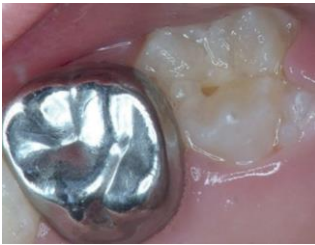Should a tooth fitted with a Hall crown subsequently develop sepsis, there are two treatment options, either pulp therapy or extraction. Pulp therapy can be carried out through the crown without needing to remove it, and the occlusal access cavity restored with a composite resin. Extraction can be undertaken as normal, though be prepared for the possibility of the crown detaching from the tooth during the procedure.



Impaction of the First Permanent Molar

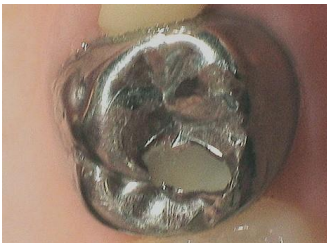If fitting a crown to second primary molars, particularly in the maxilla, before the first permanent molars are erupted, keep an eye out for the first permanent molars becoming impacted against the crown margin as they erupt. This is extremely uncommon (less than 1 in 100) and can occur even if crowns have not been fitted. At present there is no evidence to suggest Hall crowns increase this risk.

If it does occur, it can often be managed with the placement of an orthodontic separator between the second primary molar and the impacted first permanent molar. However, if it is evident that there has been significant resorption of the second primary molar, extraction of the primary molar may be indicated.



Occlusal wear

Occasionally the occlusal surface of the crown may wear through. If this occurs, the defect can often be repaired by direct restoration with composite resin.



Poorly fitting crowns

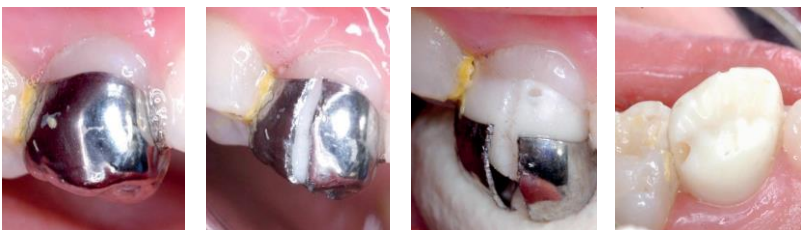It may become apparent that the crown is not adequately seated or too large for the primary molar. In these situations an assessment needs to be made of whether the position of the crown is:

- unlikely to provide an adequate seal of the caries lesion,
- the crown will impede the eruption of other teeth,
- the bite propping is excessive,
- there is occlusal interference causing mandibular displacement,
- it is not acceptable to leave the crown as is, then it needs to be removed

It is likely that either the incorrect size crown was selected at original placement, or there was an issue with seating of the crown (i.e. child was worried about biting down hard). In order to avoid the same result a second time, the operator should reflect on the initial placement and modify their approach appropriately. For example, they may place separators prior to crown placement, use a different size crown, and/or use a different approach to seating the crown.

There are 2 possible management options; the crown can be cut off. Or the occlusal part of the crown reduced with a high speed handpiece.

If the crown is to be removed and the cement has set, a high speed handpiece can be used to section the crown through the buccal and occlusal surface, following which it can easily be peeled off and remaining cement trimmed as necessary.



Some additional notes

- 1) The crowns used in the research presented here were Ni-Cro Primary Molar Crowns, cemented with AquaCem, both from 3M/ESPE. Any adjustment of the crowns was minimal, and was limited to re-moulding the crown margins in some cases with orthodontic pliers. No crown had the margin trimmed.
- 2) Crowns will try to follow the path of least resistance, and so may tilt towards the "easier" of the contacts, making it almost impossible then to ease the crown through the tight contact. Concentrate on seating the crown through the tight contact, and the easy one should take care of itself.
- 3) Patients and parents should be reassured that the child will be used to the feeling within 24 hours. It is the authors' experience that analgesia is not required. The occlusion adjusts to give even contact on both sides within weeks.
- 4) Patients should be reviewed on a normal recall schedule, and the Hall Technique should be used in conjunction with a full preventive programme.
- 5) In the authors' experience, it is usually not possible to fit a crown using the Hall Technique to a first and second primary molar in the same quadrant at the same appointment; they will need to be fitted at separate appointments.
- 6) Opposing teeth should NOT both be fitted with Hall crowns as the same appointment. Allow a minimum of 3 months for occlusal equilibration to take place and stabilise.

Bibliography and further information

“Sealing in” caries

1. Ricketts D, et al Operative caries management in adults and children. Cochrane Database of Systematic Reviews 2013, Issue 3. Art. No.: CD003808. DOI:10.1002/14651858.CD003808.pub3.
2. Marsh PD. Dental plaque as a microbial biofilm. *Caries Res.* 2004; 38(3): 204-11.
3. Riberio CCC, et al A clinical and radiographic, and scanning electron microscopic evaluation of adhesive restorations on carious dentin in primary teeth. *Quintessence Int.* 1999; 30(9):591-9.
4. Paddick JS, et al Phenotypic and genotypic selection of microbiota surviving under dental restorations. *Appl Environ Microb.* 2005; 71(5), pp. 2467-2472.
5. Going RE, et al The viability of microorganisms in carious lesions five years after covering with a fissure sealant. *J Am Dent Assoc.* 1978; 97: 455-62.
6. Handelman SL et al Clinical radiographic evaluation of sealed carious and sound tooth surfaces. *J Am Dent Assoc.* 1986; 113(5), pp. 751-754.

The Hall Technique

7. Innes NPT, Evans DJP, Stirrups DR. Sealing Caries in Primary Molars; Randomized Control Trial, 5-year Results. *J Dent Res.* 2011; 90(12) 1405-10.
<http://jdr.sagepub.com/content/90/12/1405.abstract>
8. Innes NP, Evans DJ, Stirrups DR. The Hall Technique; A randomized controlled clinical trial of a novel method of managing carious primary molars in general dental practice: Acceptability of the technique and outcomes at 23 months. *BMC Oral Health* 2007;7.
<http://www.biomedcentral.com/1472-6831/7/18>

9. Innes NPT, Stirrups DR, Evans DJP, Hall N. and Leggate M. A novel technique using preformed metal crowns for managing carious primary molars in general practice – A retrospective analysis. *Brit Dent J.* 2006; 200(8), pp. 451-454.
10. So D, Evans DJP, Borrie F, Roughley M, Lamont T, Keightley A, Gardner A, Hussein I, De Souza N, Blain K, Innes NP. Measurement Of Occlusal Equilibration Following Hall Crown Placement; IADR 2015 Boston
11. Innes NPT, Evans DJP. Modern approaches to caries management of the primary dentition. *Brit Dent J.* 2013, 214(11) 559-566.
12. Ludwig KH et al The success of stainless steel crowns placed with the Hall technique: a retrospective study. *J Am Dent Assoc.* 2014; 145(12):1248-1253
13. Santamaria RM, et al. Acceptability of different caries management methods for primary molars in a RCT. *Int J Paediatr Dent.* 2015;25(1):9-17.
14. Santamaria RM, et al. Caries Management Strategies for Primary Molars: 1-Yr Randomized Control Trial Results. *J Dent Res.* 2014;93(11):1062-9.
15. Gilchrist F, Morgan AG, Farman M, Rodd HD. Impact of the Hall technique for preformed metal crown placement on undergraduate paediatric dentistry experience. *Eur J Dent Educ.* 2013;17(1):e10-e5.
16. Bell SJ, Morgan AG, Marshman Z, Rodd HD. Child and parental acceptance of preformed metal crowns. *Eur Arch Paediatr Dent.* 2010;11(5):218-24.
17. Al-Yaseen W, Evans D, Innes N. How deep is too deep? A retrospective study of the relationship between radiographic caries lesion depth and successful outcomes with the Hall Technique. OR08-1.07. Abstracts from the 25th Congress of the International Association of Paediatric Dentistry, 1 – 4 July 2015, Glasgow, UK, July 2015. *Int J Paediatr Dent.* 25(s1), p27

Final note

The field of cariology and together with it, the management of caries in the primary dentition, is rapidly changing. Please let us know of your thoughts and comments regarding the Hall Technique, or on any other matter relating to management of the carious primary dentition.

We also welcome feedback on this manual and how it might be improved.



Dafydd Evans



Nicola Innes
n.p.innes@dundee.ac.uk



Matthew Stewart
m.z.stewart@dundee.ac.uk



Alex Keightley
a.keightley@dundee.ac.uk



Further copies of this manual can be obtained free of charge by download from Wikipedia at http://en.wikipedia.org/wiki/Hall_Technique

University of Dundee

The Hall Technique

A minimal intervention and child friendly approach to managing the carious primary molar

A Users Manual

Text copyright Nicola Innes, Dafydd Evans, Matthew Stewart & Alex Keightley

For further information on 3M ESPE Please Visit
www.3MESPE.co.uk

For further information on the Hall Technique please email
n.p.innes@dundee.ac.uk

3M ESPE have co-sponsored the clinical study on the Hall Technique but any treatment decision involving the use of the Hall Technique remains wholly the responsibility of the treating dentist.