

November Slides

Slide 1
Polymorphic Lymphocytes

Slide 2
Nothing to report

Slide 3
Nothing to report

Slide 4
See case study on the right

Slide 5
Myeloproliferative
Syndrome (CML)

Slide 6
Eosinophilia



This issue

November Slides **P.1**
 Monthly Digital Case study **P.1**
 Blast cells **.2-3**
 Blast or Lymphocyte? **P.4**

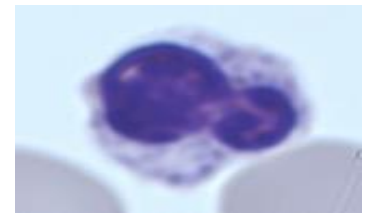
Monthly Digital Case Study Presentation November 2022, Slide 4

FBC Results

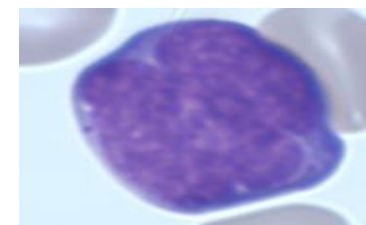
WBC 6.97* ($10^3/\text{mm}^3$)
 RBC 2.34* ($10^6/\text{mm}^3$)
 HGB 7.7 (g/dL)
 HCT 24.7 (%)
 MCV 105 (fL)
 MCH 29.5 (pg)
 MCHC 31.2 (g/dL)
 PLT 59* ($10^3/\text{mm}^3$)

Slide review
 Male age 66
 Clinical Details
 Myelofibrosis

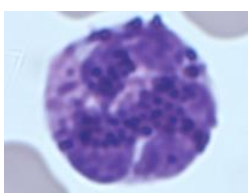
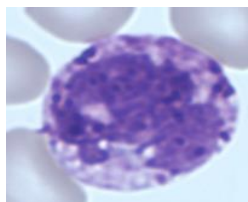
Rare erythroblasts



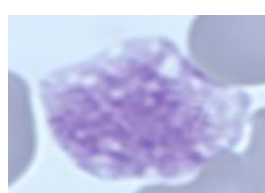
Rare blasts



Basocytes (+++)

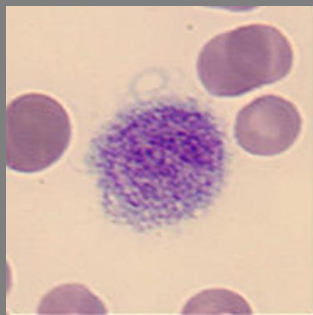

Macroplatelets (+++)



Monthly Morphology Quiz

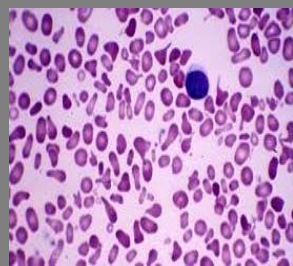Look closely at the slide below:



What do you think it is?

Last month's cell Quiz:

Which of the below would you associate with a film appearance like this?



- A) Sickle cell
- B) Hereditary Elliptocytosis
- C) Haemolysis

Right answer: B

The Quiz slide shows hereditary elliptocytosis. You can see the red cells (RBC) appear **elongated, oval**, or **elliptically shaped** on the peripheral blood smear. Hereditary spherocytosis is characterised by haemolysis of spheroidal RBCs and anaemia. This is a rare autosomal dominant disorder. It is caused because of a weakness in the horizontal linkages found in the skeleton of the membrane. This is caused when there is a defective dimer-dimer interaction, or a defective spectrin-actin 4.1R junction complex. Spectrin is the main component of the cells membrane, crucial in maintaining the shape and structure.

How to spot a blast cell

Blast cells are precursor cells to mature circulating cells. These cells are usually found in low numbers in the bone marrow and generally not in significant numbers in circulating blood.

The ability to recognise a blast cell in a blood film is perhaps one of the most important morphology skills.

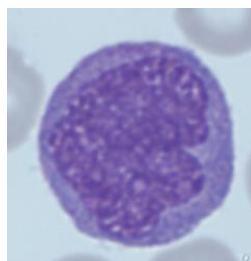
Blast cells are seen in severe infections, medications (GCSF), bone marrow transplants, and hematopoietic neoplasms.

Acute leukaemia's are the most important to spot, as these can rapidly lead to death.

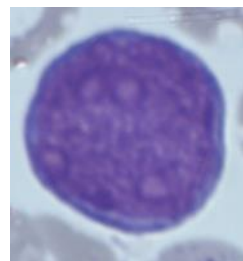
Spotting a blast cell

Unfortunately, there is no single characteristic that indicates a blast. In general, blasts are cells that have a large nucleus, immature chromatin, a prominent nucleolus, scant cytoplasm, and few or no cytoplasmic granules. Blasts may have some, or all of these characteristics:

- **Cell size** - blasts are often medium to large cells. They are usually larger than a lymphocyte and at least the size of a monocyte.
- **Large nucleus** - most of the cell is taken up by the nucleus - they have a high nuclear to cytoplasmic ratio.
- **Immature chromatin** - the nuclear chromatin looks as if it is made of fine dots. Imagine chromatin as many tiny points made by the tip of a sharp pencil on a piece of paper.
- **Prominent nucleolus**. Nucleolus or nucleoli are structures within the nucleus which appear as round less stained areas. The presence of nucleoli can be helpful in defining the specificity of the cell.
- **Nuclear membrane**- usually follows the shape of the cytoplasm membrane.



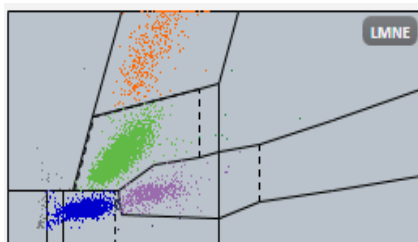
Blast Cells



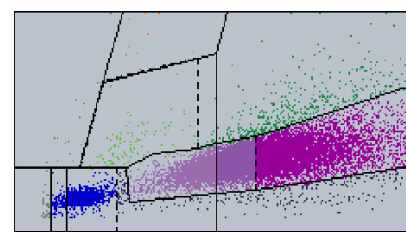
It is really important when assessing a blood film to pull all the available information available together, this includes current results, plots from the instrument, any clinical details or previous results.

The LMNE channel on all the [Yumizen H analysers](#) can be used to assess if abnormal cells are present. The LMNE channel plots Cell Volume on the X axis and Cell Absorption on the Y axis is a visual marker for abnormal cells. On the [Yumizen H analysers](#) the blast cell flag is a multiparameter flag using measurements from 2 different channels (the Baso and LMNE channel), together with diff can be the first indication of presence of Blasts.

LMNE from normal patient



LMNE from AML patient



Looking at the full blood count results carefully is essential when looking at peripheral blood films, as they go hand-in-hand to give the technician as much information as possible on the sample.

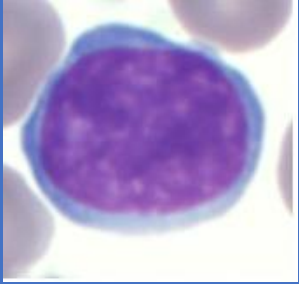
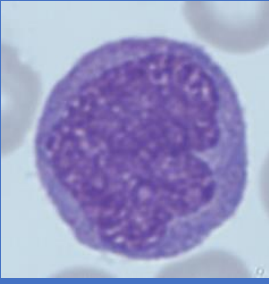
There are a lot of parameters, so try to focus on the white blood cell count (WBC), haemoglobin (Hb), and platelet count (PLT) initially.

Look at the strength of the signal on the instrument, flags (*****). The more parameters that are abnormal, the more cause for concern.

The more an individual parameter is abnormal, the cause for concern. e.g only mild anaemia (WBC normal, Hb slightly decreased, PLT normal; not too worried) vs. severe pancytopenia (WBC **markedly decreased**, Hb **markedly decreased**, PLT **marked decreased**; worried).

Blast or Lymphocyte??

It is often difficult, especially to trainee morphologists (and sometimes those with vast experience) to distinguish between a lymphocyte and a blast cell. Here is a guide to help differentiate blasts from lymphocytes:

Feature	Reactive Lymphocyte	Blast Cell
		
Size	Variable in size	Usually larger than a lymphocyte
Chromatin	Clumped	Fine
Nucleoli	Absent	May be present
Cytoplasm	Deep blue smooth	Grainy
Shape	Irregular	Round, may be indented

QSP 2.0

Available as a single use license and a site license which allows up to 50 concurrent users.

To find out more, [contact us](#).

Bibliography

Malaysian J Pathol 2020; 42(1): 37 – 49

Is this a blast? An illustrated practical review on peripheral blood smear examination in the paediatric patient Gary ROSE¹, Heidi REINHARD¹, Samir B. KAHWASH^{1,2}

<https://eclinpath.com/hematology/morphologic-features/white-blood-cells/big-blue-cells/>

Editorial Team

Kelly Duffy
Andrew Fisher

About us

HORIBA UK Limited
Kyoto Close
Moulton Park
Northampton, UK
NN3 6FL

HORIBA Medical
Parc Euromédecine, 390
Rue du Caducée, 34790,
France

www.horiba.com/medical

