

How Do I Retake PREP® Subspecialty and NeoReviewsPlus™ (2022 and Prior)

1. Verify that you have answered all the questions in the assessment.

NeoReviewsPlus

Self-Assessment PREP Pearls Editorial Board

Home Overview January February **March** April May June July August

Course Status

March

Print

PROGRESS Total Questions: 8 Total Answered: 5 Correct: 3 Assessment History

View: All (8) Page 7 of 10

Question: 6

You are caring for a 36 weeks' gestation neonate with hypoxic-hypercarbic respiratory failure. The mother received good prenatal care and the fetal ultrasonogram was normal at 17 weeks' gestation. She presented on the day of delivery with a chief complaint of decreased fetal movement. Spontaneous recurrent late fetal heart rate decelerations were noted and led to an emergent cesarean delivery. Rupture of the membranes at the time of delivery revealed scant amniotic fluid. The neonate was intubated shortly after birth for severe respiratory distress.

Vital signs include a temperature of 37.1°C, a heart rate of 174 beats/min, and blood pressure of 89/52 mm Hg. Physical findings are notable for slight deformational asymmetry of the head, diminished breath sounds bilaterally, marked abdominal distension, and rocker bottom feet. Following the administration of surfactant, the neonate continues to be managed with high-frequency ventilation, 100% oxygen, and inhaled nitric oxide, achieving a preductal saturation of 92% and a postductal saturation of 87%. A chest radiograph is performed (Figure 1).

Of the following, the test MOST likely to diagnose this neonate's underlying condition is

2. If you still have unanswered questions, use the question view drop down to filter the unanswered questions.

NeoReviewsPlus

Self-Assessment PREP Pearls Editorial Board

Home Overview January February **March** April May June July August

Course Status

March

Print

PROGRESS Total Questions: 8 Total Answered: 5 Correct: 3 Assessment History

View: All (8) Page 7 of 10

All Unanswered Incorrect

Category ACGME Question 1 Question 2 Question 3 Question 4 Question 5 Question 6 Question 7

36 weeks' gestation neonate with hypoxic-hypercarbic respiratory failure. The mother received good prenatal care and the fetal ultrasonogram was normal at 17 weeks' gestation. She presented on the day of delivery with a chief complaint of decreased fetal movement. Spontaneous recurrent late fetal heart rate decelerations were noted and led to an emergent cesarean delivery. Rupture of the membranes at the time of delivery revealed scant amniotic fluid. The neonate was intubated shortly after birth for severe respiratory distress.

temperature of 37.1°C, a heart rate of 174 beats/min, and blood pressure of 89/52 mm Hg. Physical findings are notable for slight deformational asymmetry of the head, diminished breath sounds bilaterally, marked abdominal distension, and rocker bottom feet. Following the administration of surfactant, the neonate continues to be managed with high-frequency ventilation, 100% oxygen, and inhaled nitric oxide, achieving a preductal saturation of 92% and a postductal saturation of 87%. A chest radiograph is performed (Figure 1).

test MOST likely to diagnose this neonate's underlying condition is

3. Continue to answer each question. When you've completed all the questions, you will see the option to Take Again.

NeoReviewsPlus

Self-Assessment PREP Pearls Editorial Board

Home Overview January February **March** April May June July August

Course Status

March

Print

✓ **CONGRATULATIONS** THIS ASSESSMENT IS NOW COMPLETE. **CLAIM CREDIT**

PROGRESS Total Questions: 8 Total Answered: 8 Correct: 5 Assessment History **Take Again**

Learner Mode View: All (8) Page 9 of 10

Question: 8

A female infant is delivered at 27 weeks of gestation with a birthweight of 850 g to a mother with premature rupture of membranes and preterm labor. The infant has been in your neonatal intensive care unit for 5 weeks, and has been receiving enteral feedings over 90 minutes by gavage tube; her parents hold her upright for 45 minutes after each feeding. She has mild apnea and bradycardia events daily and is receiving caffeine. The nursing staff is concerned that reflux may be causing the apnea and bradycardia events, and asks you to consider pharmacologic therapy for reflux. Metoclopramide, ranitidine, erythromycin, and omeprazole are being discussed.

Of the following, the complication MOST associated with a medication that acts via the 5-hydroxytryptamine (5-HT) receptor is

NeoReviewsPlus

Self-Assessment PREP Pearls Editorial Board

Home Overview January February **March** April May June July August

Course Status

March

Print

⚠ **FAILING SCORE** YOU HAVE NOT MET THE MINIMUM PASSING SCORE FOR THIS ASSESSMENT. **TAKE AGAIN**

YOUR SCORE: 37.5% MINIMUM SCORE: 62%

PROGRESS Total Questions: 8 Total Answered: 8 Correct: 3 Assessment History **Take Again**

Learner Mode View: All (8) Page 9 of 10

Question: 8

A female infant is delivered at 27 weeks of gestation with a birthweight of 850 g to a mother with premature rupture of membranes and preterm labor. The infant has been in your neonatal intensive care unit for 5 weeks, and has been receiving enteral feedings over 90 minutes by gavage tube; her parents hold her upright for 45 minutes after each feeding. She has mild apnea and bradycardia events daily and is receiving caffeine. The nursing staff is concerned that reflux may be causing the apnea and bradycardia events, and asks you to consider pharmacologic therapy for reflux. Metoclopramide, ranitidine, erythromycin, and omeprazole are being discussed.

Of the following, the complication MOST associated with a medication that acts via the 5-hydroxytryptamine (5-HT) receptor is

4. Select which questions you would like to retake.

Please Confirm

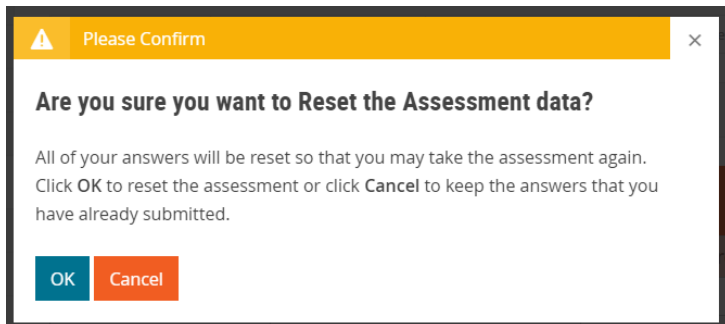
Are you sure you wish to take this assessment again?

Retake All Questions Retake Missed Questions Cancel

Question: 8

5. After completing one cycle of the assessment, you will also have a separate option to Reset the Assessment at any time. **Please note that this option will reset the activity and will not carry over any of your completed answers from your current cycle.**

The screenshot shows the NeoReviewsPlus assessment interface. At the top, there are navigation links for 'Self-Assessment', 'PREP Pearls', and 'Editorial Board'. The main content area is titled 'March' and includes a 'Print' icon. A progress bar shows 'PROGRESS' with 'Total Questions: 8', 'Total Answered: 3', and 'Correct: 3'. There are buttons for 'Assessment History' and 'Reset Assessment' (circled in red). Below the progress bar, there are dropdown menus for 'Learner Mode' and 'View: Unanswered (5)', and a page indicator 'Page 4 of 10'. The question is titled 'Question: 3' and describes a pediatrician consulting about a term newborn with an abnormally shaped head. The question asks for the most appropriate screening test for this newborn, with four options: A. audiogram, B. echocardiogram, C. electroencephalogram, and D. renal ultrasonogram. There are 'Submit' and 'Reset' buttons at the bottom of the question area.



If you need more help to retake your assessments, please contact Member and Customer Care at 866-843-2271 or email us at mcc@aap.org for further assistance.